

Note

## A rare stranding event of the short beaked common dolphin (*Delphinus delphis*) in the Eastern Tunisian coastline

Olfa CHAIEB , Kaouthar MAATOUK  & Mohamed Nejmeddine BRADAI 

University of Carthage. Institut National des Sciences et Technologies de la Mer, Tunisia

\*Correspondence: [olfa.chaieb@instm.rnrt.tn](mailto:olfa.chaieb@instm.rnrt.tn)

Received: 30/01/2023; Accepted: 12/11/2023; Published: 07/12/2023

**Abstract:** A short beaked common dolphin (*Delphinus delphis*) was found stranded on March 3rd, 2021, on Hammamet beach (Gulf of Hammamet, Central-Eastern Tunisia). This is a rare stranding event since it represents the third documented stranded individual reported on Tunisian coastline for half a century. Necropsy of the freshly dead female dolphin was conducted to know the presumable cause of death. The pregnant dolphin was bearing a mid-term female fetus with fully developed organs. Detailed biometric data were taken for both individuals. The necropsy didn't reveal any visible factor causing the death of the animal. The digestive tract of the weakened female was totally empty with no food remains or a strange, ingested object. Samples were collected and preserved in the tissue bank of the national stranding network at the Institut National des Sciences et Technologies de la Mer (INSTM). The freshly dead fetus is preserved at the oceanographic museum of INSTM for scientific collection. The rare stranding of this species observed here, added to the small number of individuals observations in water would be attributed to the small population of this species frequenting Tunisian waters. This note improves knowledge on this poorly studied species in the south-central Mediterranean area.

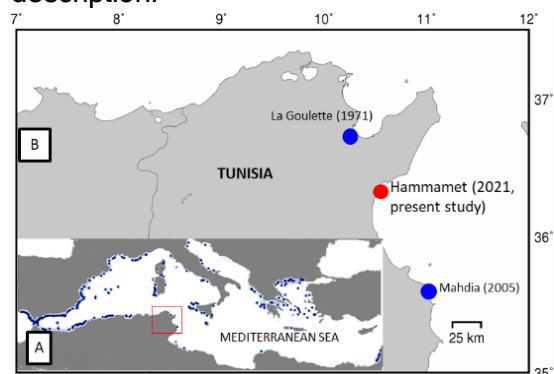
**Keywords:** Records; common dolphin; *Delphinus delphis*; stranding; necropsy; Tunisia; South-Central Mediterranean.

### 1. Introduction

In the past, knowledge about cetaceans in Tunisia were limited and based on disparate observations (Ben Naceur et al., 2004; 2005; Bradai, 1991; Bradai & Ghorbel, 1998; Bradai et al., 2002; Ktari-Chakroun, 1980). During the last decade, an increasing attention has been paid to these endangered species with focus on population distribution, abundance and stranding (Aissi et al., 2015; Benmessaoud

et al., 2017; 2018; Karaa et al., 2009). Stranding monitoring provides fundamental information for better understanding the biology, the ecology and the pathology of these species. Almost half of Mediterranean species have been stranded along Tunisian coastlines mostly composed of the bottlenose dolphin then in lesser extent the fin whale, with higher concentration in the Gulf of Gabes (Southern Tunisian, Bradai & Karaa, 2015).

The short beaked common dolphin *Delphinus delphis* (Linnaeus, 1758), is listed by the IUCN red List as endangered species in the Mediterranean area. This species rarely stranded on Tunisian coasts. Only two stranding events were documented in the past (Fig. 1). The first event was an alive adult stranded on La Goulette beach (Northern of Tunisia) in 1971, which died few days later (Kartas, 1971). The second stranding occurred in 2005 along the Central Tunisian coasts, at Mahdia. No more details were provided about this event (karaa et al., 2009). It appears that stranding is more abundant in the extreme western Mediterranean basin particularly in the South of Spain and in the North Eastern part mainly in Greece. Lesser records were observed in the central Mediterranean region (Vella et al., 2021; Fig. 1.A). In Tunisia, information on common dolphin is scattered. Population presence was documented on some occasions only in the North, mainly offshore waters of Bizerte (Ben Naceur et al., 2004; 2005) and inshore and offshore of Kelibia waters (Benmessaoud et al., 2018). Here we report a new stranding event occurring in 2021 with detailed description.

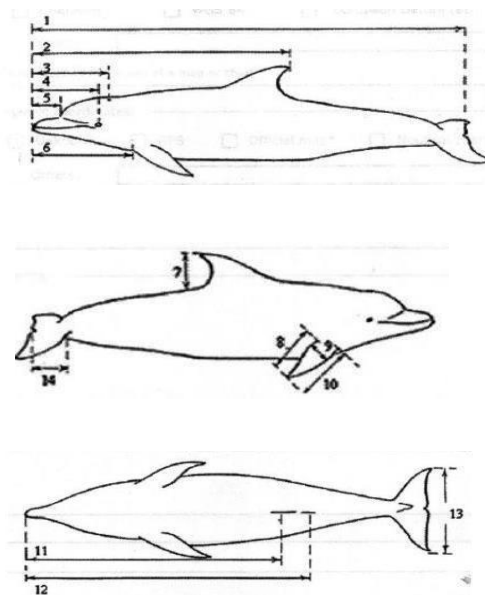


**Figure 1.** Stranding distribution of *Delphinus delphis*. A: in the Mediterranean (by Vella et al., 2021), B: in Tunisia. Red square represents the study area, blue dots indicate historical data, the red dot indicates the present case study.

## 2. Materials and methods

In 2004, the Institut National des Sciences et Technologies de la Mer launched the

national stranding network to monitor cetacean strandings in Tunisia. This network includes three teams operating along the entire Tunisian coastline, from north to south. On March 3, 2021, the team from the central region was alerted to a dolphin stranding on the beach of Hammamet ( $36^{\circ}24'11.6''N$   $10^{\circ}35'41.1''E$ , central-eastern Tunisia, Fig.1). The animal was found dead on the beach, in the early morning by a local citizen that alerted the municipality of Hammamet. The team moved to the stranding locality and transported the carcass to the institute for necropsy. Detailed body measurements were recorded according to the figure 2. Necropsy was performed following the standard protocol (Kuiken & García Hartmann 1991). Tissue samples were collected and preserved in alcohol. Finally, the carcass was buried at the INSTM garden.



**Figure 2.** Body measurements

1: total body length (TBL); 2: tip of rostrum to tips of dorsal fin (TTD); 3: rostrum to blowhole (TB); 4: rostrum to the eye (TE); 5: rostrum to end of gape (TGA); 6: rostrum to front of pectoral fin (TFP); 7: height of dorsal fin (HD); 8: inner length pectoral fin (ILP); 9: width pectoral fin (WP); 10: outer length of pectoral fin (OLP); 11: rostrum to genital slit (TG); 12: rostrum to anus (TA); 13: total fluke span (TFS); 14: width of the fluke (WF).

### 3. Results and discussion

The stranded short beaked common dolphin was freshly dead. The skin and internal organs were not decomposed and were pinkish colored. The weakened female did not show any injuries or external parasites. The necropsy showed that the female dolphin was pregnant and was carrying a mid-term female fetus measuring 62 cm total length and weighed 3 Kg (Fig. 3). Detailed morphometric measurements of both individuals were given in table 1. The mother was a 201 cm in length and weighed 75 Kg. Its total length corresponded to the mean body length of a mature female common dolphin, attained approximately at 9 years old. Differences exist with males which generally reach maturity at 11 years old with a mean total body length of 213 cm (Murphy & Rogan, 2006). It is noteworthy to mention that total body lengths at maturity show geographical differences for both sexes, being larger in the North-East Atlantic and smaller in the black sea (Murphy & Rogan, 2006).



**Figure 3.** Stranded adult female of short beaked common dolphin with her fetus

Samples of skin, fat, muscle and liver were collected and preserved in the tissue bank of the national stranding network. The fresh fetus will be preserved in the oceanographic museum of the INSTM of Salammbô. Internal organs of the mother didn't show any abnormality. The heart, the liver, the lungs, and the Kidneys were weighed and recorded in table 2. The digestive tract was completely empty and measured 1540 cm of total length.

Information on organ weights in wild migratory megafauna, such as cetaceans, is valuable for several reasons: 1/to provide data for comparison with other marine or terrestrial species, 2/to help improve knowledge of the physiology and overall biology of these animals, and 3/to provide baseline data that may be used to evaluate pathological aspects.

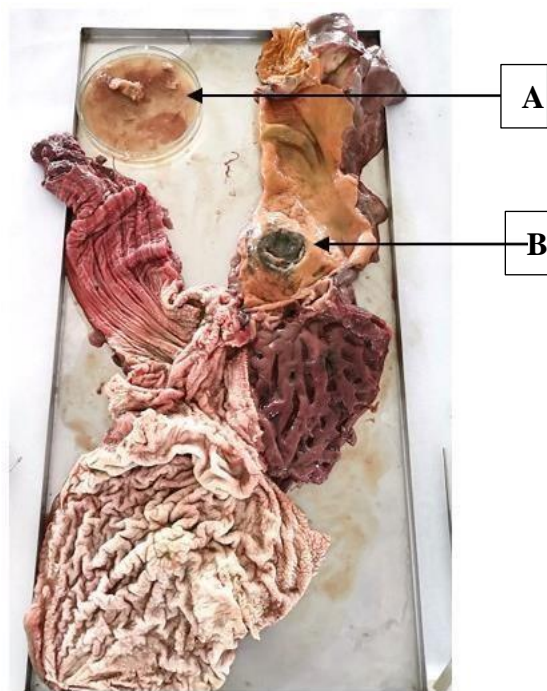
**Table 2.** Organs weight of the mother dolphin

Organs	Heart	Liver	Lungs	Kidney
Weight (g)	498	1570	1360	621

The examination of the stomach revealed the presence of the nematode parasite *Anisakis* spp. in the three stomach compartments with a low level of parasitism (Fig. 4). We also noticed the presence of a hard greenish nodule in the lumen of the first portion of the pyloric stomach, which could be due to an old healed ulcer.

**Table 1.** Morphometric measurements of both individuals  
(\*For numbers, refer to figure 2)

*	1	2	3	4	5	6	7	8	9	10	11	12	13	14
<b>Mother</b>	201	125	32	33	14	46	18	22	10	29	139	145	41	13
<b>Fetus</b>	62	-	13	13	4	16.5	6	11.5	4	12.5	45.5	47	14	6



**Figure 4.** Dissected stomach of the stranded animal. A: Nematode *Anisakis* spp ; B: Nodule

#### 4. Discussion

The rare stranding events of common dolphins ever recorded in Tunisia would be attributed to the small population residing in our waters. In the Mediterranean, Common Dolphin population has undergone a widespread and significant decline over the past 30-40 years (Bearzi et al. 2003). Today, Common Dolphins remain relatively abundant in the westernmost portion of the basin, the Alboran Sea. There are sparse records off the coast of Algeria, Italy, and Malta (Bearzi et al. 2003; Vella et al. 2021). They can be found in portions of the eastern Ionian Sea and in the Aegean Sea (Frantzis and Herzing 2002).

The stranding of a pregnant female assumes that the population is reproducing in Tunisian area. This finding is concordant with the results found by Benmessaoud et al. (2018) who observed a resident population in the northeastern part of Tunisia (Kelibia, Gulf of Hammamet). The authors mentioned the occurrence of

immatures in mixed pod of short beaked dolphin in Kelibia waters. They consequently assume that the northeastern coasts can be considered as a breeding area (Benmessaoud et al., 2018). Regarding the size of the fetus, it would have been born in a couple of months, during the upcoming summer of 2021. Prenatal specimens from stranded pregnant cetaceans are difficult to obtain and are usually in bad condition. The preservation of the fresh fetus in the INSTM museum would be beneficial for cetacean research. This will provide baseline data for comparison with other cetacean species. This will also improve knowledge of embryology aspects for the species as well as evolutionary studies.

Advanced analysis on microbiology and histopathology couldn't be performed to identify the presumable cause of death. However, the denutrition and the poor health condition of the mother may result from infection, very frequent in cetaceans. A variety of diseases and parasites can be responsible for dolphin deaths. Dolphins may suffer from viral, bacterial, and fungal infections. In addition, they may develop stomach ulcers, skin diseases, tumors, heart disease, urogenital disorders, and respiratory disorders.

*Anisakis* spp are parasites that, as adults, live in the digestive system of marine mammals and humans, which represent their definitive hosts (Romero et al., 2014). The life cycle of the parasite involves planktonic crustaceans as first intermediate hosts, while fish and squids are intermediate hosts (Mattiucci et al., 2018). Gastric ulcers associated with the presence of *Anisakis* spp. are often reported in stranded cetaceans (Abollo et al., 1998; Lehnert et al., 2005; Motta et al., 2008). In most of the studies, they do not represent the cause of death and stranding of the cetaceans. In this study, the low level of parasitism observed in the stomach of the Common dolphin would not most



probably be the cause of death. However, in some cases, severe infections can lead to gastric wall perforations, consequently causing peritonitis and death of the animal (Jaber et al., 2006).

### Acknowledgments:

This work has been presented in the 5<sup>th</sup> Conference on Cetacean Conservation in South Mediterranean Countries (CSMC5). We acknowledge the use of Maptool to draw the map [www.seaturtle.org/maptool](http://www.seaturtle.org/maptool).

### References

1. Abollo, E., López, A., Gestal, C., Benavente, P. & Pascual, S. (1998). Long-term recording of gastric ulcers in cetaceans stranded on the Galician (NW Spain) coast. *Diseases of Aquatic Organisms*, 32, 71–73. <https://doi.org/10.3354/dao032071>
2. Aissi, A., Arcangeli, R., Crosti, M. N., Daly Yahia, B., Loussaief, A., Moulins, G., Pellegrino, M., Rosso, L., Tringali, M. & Tepsich, P. (2015). Cetacean occurrence and spatial distribution in the Central Mediterranean Sea using ferries as platform of observation. *Russian Journal of Marine Biology*, 41, 343–350. <https://doi.org/10.1134/S1063074015050028>
3. Bearzi, G., Reeves, R. R., Notarbartolo di Sciara, G., Politi, E., Cañadas, A., Frantzis, A., et al. (2003). Ecology, status and conservation of short-beaked common dolphins, *Delphinus delphis*, in the Mediterranean Sea. *Mammal Review*, 33(3–4), 224–252 [10.1046/j.1365-2907.2003.00032.x](https://doi.org/10.1046/j.1365-2907.2003.00032.x)
4. Benmessaoud, R., Cherif, M. & Aloui-Bejaoui, N. (2013). Baseline data on abundance, site fidelity and association patterns of common bottlenose dolphins (*Tursiops truncatus*) off the northeastern Tunisian coast (Mediterranean Sea). *Journal of Cetacean Research and Management*, 13(3), 211–219. <https://doi.org/10.47536/jcrm.v13i3.538>
5. Benmessaoud, R., Cherif, M., Alessi, J., Ammar, Y., Koched, W. & Aloui-Bejaoui, N. (2017). Bottlenose dolphin's interactions with aquaculture farm in the eastern of Tunisia: A preliminary study. *Bulletin de l'Institut National des Sciences et Technologies de la Mer*, 44, 51–60. <https://www.instm-bulletin.tn/index.php/bulletin/article/view/444>
6. Benmessaoud, R., Cherif, M., Koched, W. & Karaa, S. (2018). Essai de la technique de Photo-identification pour l'étude de la population du dauphin commun (*Delphinus delphis*, Linné 1758) de la région de Kélibia, Tunisie. *Bulletin de l'Institut National des Sciences et Technologies de la Mer*, 45, 15–18. <https://www.instm-bulletin.tn/index.php/bulletin/article/view/86>
7. Ben Naceur, L., Gannier, A., Bradai, M.N., Drouot, V., Bourreau, S., Khalfallah, N., Mrabet, R. & Bdioui, M. (2004). Recensement du grand dauphin *Tursiops truncatus* dans les eaux Tunisiennes. *Bulletin de l'Institut National des Sciences et Technologies de la Mer*, 31, 75–81. <https://www.instm-bulletin.tn/index.php/bulletin/article/view/759>
8. Ben Naceur, L., Gannier, A., Bradai, M.N., Jribi I., Ali H., Makhoulfi, M. & Karaa, S. (2005). Compagne d'observation des cétacés dans les eaux tunisiennes : la Galite. Acte de la quatorzième conférence internationale pour la protection des mammifères marins en Méditerranée occidentale, pp. 16.

9. Bradai, M.N. (1991). Nouvelles mentions de Delphinidae. *Revue de l'Institut National Agronomique de Tunisie*. Tunis, 6(2), 169 – 171.
10. Bradai, M.N., & Ghorbel, M. (1998). Les cétacés dans la région du golfe de Gabes. Premières mentions de deux Balaenopteridae: *Megaptera noveangliae* et *Balaenoptera acutorostrata*. Actes des 3ème journées Tunisiennes des Sciences de la Mer, 9-11.
11. Bradai, M.N., Elouaer, A., Elabed A. & Maatoug, K. (2002). Sauvetage de deux rorquals communs *Balaenoptera physalus* échoués vivants sur les côtes tunisiennes. *Acte de la onzième conférence internationale pour la protection des mammifères marins en Méditerranée occidentale*, 11, 52-53.
12. Bradai, M.N. & Karaa, S. (2015). *Les tortues, les dauphins et les baleines de Tunisie: biodiversité et effort de conservation*. INSTM. 40p. <http://hdl.handle.net/1834/9067>
13. Frantzis, A., & Herzing, D. (2002). Mixed-species associations of striped dolphins (*Stenella coeruleoalba*), shortbeaked common dolphins (*Delphinus delphis*), and Risso's dolphins (*Grampus griseus*) in the Gulf of Corinth (Greece, Mediterranean Sea). *Aquatic Mammals*, 28(2), 188-197
14. Jaber, J.R., Pérez, J., Arbelo, M., Zafra, R. & Fernández, A. (2006). Pathological and immunohistochemical study of gastro-intestinal lesions in dolphins stranded in the Canary Islands. *The Veterinary record*, 159, 410-414. <https://doi.org/10.1136/vr.159.13.410>
15. Karaa, S., Bradai, M.N., Jribi, I., Attia, H. & Bouain, A. (2012). Status of cetaceans in Tunisia through analysis of stranding data from 1937 to 2009. *Mammalia*, 76(1), 21-29. <https://doi.org/10.1515/MAMM.2011.100>
16. Kartas, F. (1971). Echouage d'un Dauphin à la Goulette. *Bulletin de l'Institut National Scientifique et Technique d'Océanographie et de Pêche de Salammbô*, 2 (2), 269-270. <https://www.instm-bulletin.tn/index.php/bulletin/article/view/1660>
17. Ktari-Chakroun, F. (1980). Les cétacés des côtes tunisiennes. *Bulletin de l'Institut National Scientifique et Technique d'Océanographie et de Pêche de Salammbô*, 7, 139-149. <https://www.instm-bulletin.tn/index.php/bulletin/article/view/1144>
18. Kuiken, T. & García-Hartmann, M. (1991). Proceedings 1<sup>st</sup> ECS workshop on cetacean pathology: dissection techniques and tissue sampling. *European Cetacean Society Newsetter*, 17, (Special Issue), Saskatoon.
19. Lehnert, K, Raga, J.A. & Siebert, U. (2005). Macroparasites in stranded and bycaught harbour porpoises from German and Norwegian waters. *Diseases of Aquatic Organisms*, 64(3), 265-269. <https://doi.org/10.3354/dao064265>
20. Mattiucci, S. & Nascetti, G. (2008). Advances and trends in the molecular systematics of anisakid nematodes, with implications for their evolutionary ecology and post-parasite co-evolutionary processes. *Advances in Parasitology*, 66, 47-148. [https://doi.org/10.1016/S0065-308X\(08\)00202-9](https://doi.org/10.1016/S0065-308X(08)00202-9)
21. Motta, MRA., Pinheiro, DCSN., Carvalho, V.L., Viana, DDA., Vicente, ACP., Iñiguez, AM. (2008). Gastric lesions associated with the presence of *Anisakis* spp. Dujardin, 1845 (Nematoda: Anisakidae) in cetaceans

- stranded on the coast of Ceara, Brazil. *Biota Neotropica* 8(2): 91–95. <https://doi.org/10.1590/S1676-06032008000200010>
22. Murphy, S. & Rogan, E. (2006). External morphology of the short-beaked common dolphin, *Delphinus delphis*: Growth, allometric relationships and sexual dimorphism. *Acta Zoologica*, 87 (4), 315-329. <https://doi.org/10.1111/j.1463-6395.2006.00245.x>
23. Romero, M.A., Fernández, M., Dans, S.L., García, N.A., González R., Crespo, E.A. (2014). Gastrointestinal parasites of bottlenose dolphins *Tursiops truncatus* from the extreme southwestern Atlantic, with notes on diet composition. *Diseases of Aquatic Organisms*. 108 (1), 61-70. <https://doi.org/10.3354/dao02700>
24. Vella, A., Murphy, S., Giménez, J., De Stephanis, R., Mussi, B., Vella, J.G., Doukara, K.L., & Space, D.S. (2021). The conservation of the endangered Mediterranean common dolphin (*Delphinus delphis*): Current knowledge and research priorities. *Aquatic Conservation: Marine and Freshwater Ecosystems*, 31(S1), 110–136. <https://doi.org/10.1002/aqc.3538>

